

Replantation of an Autoclaved Autogenous Segment of Bone for Treatment of Chondrosarcoma

LONG-TERM FOLLOW-UP*

BY WILLIAM S. SMITH, M.D.†, AND STEVEN STRUHL, M.D.‡, ANN ARBOR, MICHIGAN

From the Section of Orthopaedic Surgery, University of Michigan Hospital, Ann Arbor

ABSTRACT: Seven patients who had a low-grade chondrosarcoma of the proximal part of the humerus or femur were treated by resection, autoclaving of the excised segment, and reinsertion of that segment with supplementary fresh autogenous grafts. The length of

follow-up ranged from fourteen to twenty-four years, and sequential roentgenograms were made during the follow-up period. A biopsy of the autoclaved segments was done in one patient eleven years after the operation, and examination of the specimen showed predominantly

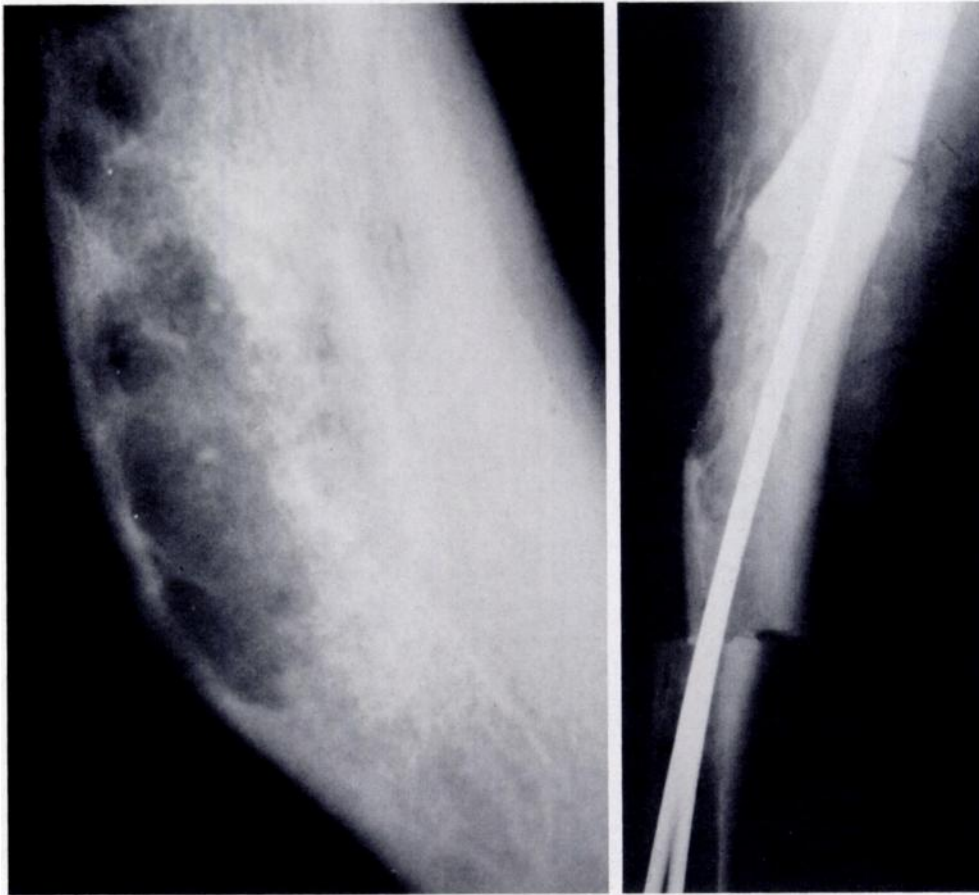


FIG. 1-A

FIG. 1-B

Figs. 1-A, 1-B, and 1-C: Case 1.

Fig. 1-A: Preoperative roentgenogram of a lesion in the femoral shaft. Intramedullary calcific deposits are seen at the apex of the deformity.

Fig. 1-B: Roentgenogram made two months after a segmental resection was performed. The autoclaved segment was reinserted and surrounded by massive autogenous iliac bone, and a distally split intramedullary device was used for fixation.

* No benefits in any form have been received or will be received from a commercial party related directly or indirectly to the subject of this article. No funds were received in support of this study.

† Section of Orthopaedic Surgery, University of Michigan Hospital, 1500 East Medical Center Drive, Ann Arbor, Michigan 48109.

‡ Department of Orthopaedics, Montefiore Medical Center, Bronx, New York 10467.

live bone; there were very few spicules of dead bone.

Although the principal roentgenographic changes were demonstrated by the end of the first year, serial roentgenograms showed a continuing process of remodeling for two decades. No secondary procedures

were required for treatment of fracture, resorption, infection, or loss of function.

In the past few decades, better staging and surgical techniques have improved the prognosis of patients who have a malignant bone tumor^{5-8,11,16,17}. However, as more radical resections have been developed, the need for suitable substitutes for the resected segment has become evident^{17,20}.

This report is a follow-up of a series of patients whose cases were published in 1975²³. Only low-grade, well differentiated chondrosarcomas that were confined to the intraosseous compartment were selected for the treatment under study. Modern techniques for imaging, such as computed tomography, were not available at the time of the original study, so only standard roentgenograms and laminagrams were made to assess cortical penetration. After we had resected the segment containing the tumor, the resected

bone was autoclaved at 135 degrees Celsius for twelve to fifteen minutes at a pressure of 0.2 megapascal (twenty-nine pounds per square inch). The bone was then implanted in its former site and fixed with an intramedullary rod or a long-stem uncemented shoulder or hip endoprosthesis. The segment was then surrounded with a massive fresh autogenous bone graft from one or both ilia. Follow-up ranged from fourteen to twenty-four years.

Case Reports

CASE 1. A thirty-three-year-old man had increasing pain in the right thigh for three months. Roentgenograms demonstrated an angular deformity at the junction of the proximal and middle thirds of the femur as well as an associated area of rarefaction at the apex of the deformity with minute calcific deposits in the rarefied area (Fig. 1-A). The history included a fracture of the shaft of the right femur at the age of two years. An open biopsy showed a low-grade chondrosarcoma.

At operation, a twenty-centimeter segment of bone was removed,

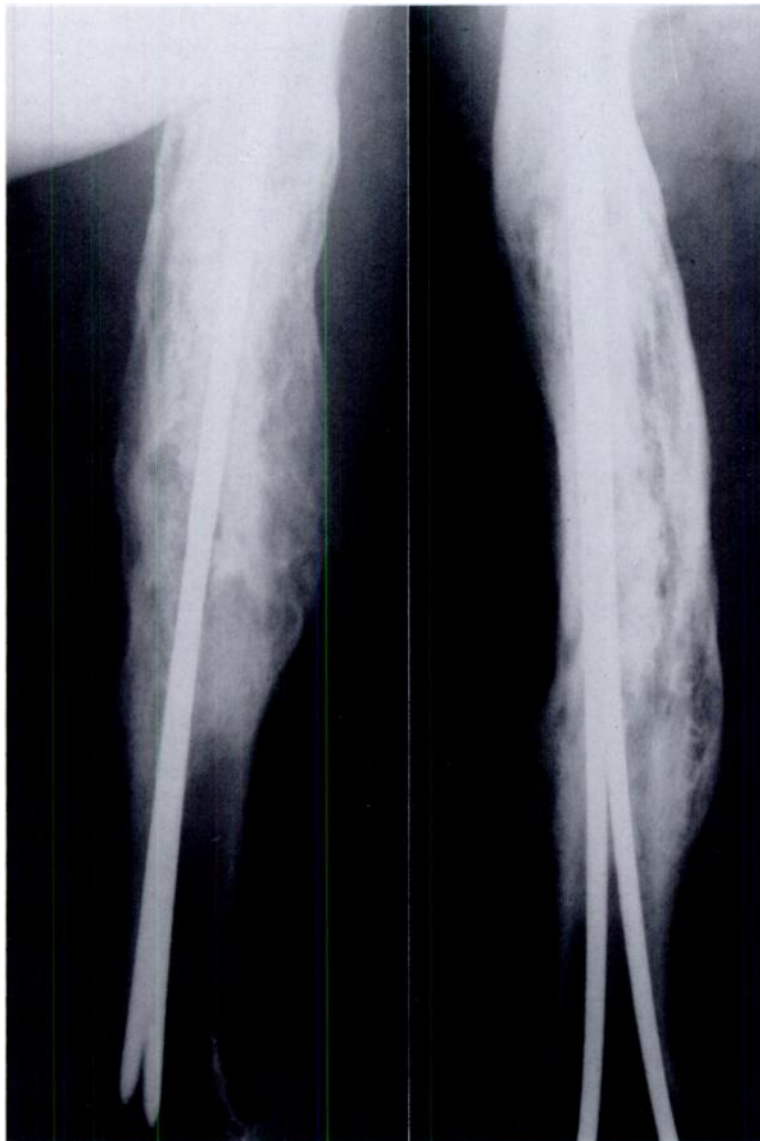

FIG. 1-C

Twenty-four years after the operation, remnants of the autoclaved segment are barely evident. The density of the intercalary segment approaches that of the parent bone, and the trabeculae of the original femoral shaft are confluent with the remainder of the autoclaved segment. Remodeling is advanced but incomplete.

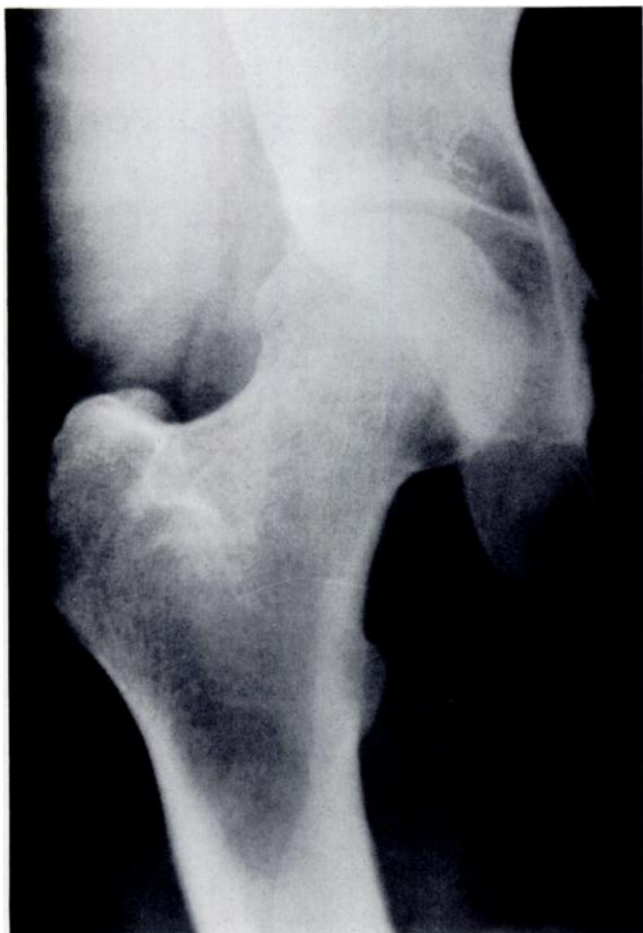

FIG. 2-A

Figs. 2-A, 2-B, and 2-C: Case 2.

Fig. 2-A: A poorly defined subtrochanteric lytic lesion. A diagnosis of low-grade chondrosarcoma was established by an open biopsy.

autoclaved, and reinserted, as described, and a split intramedullary rod was used for fixation (Fig. 1-B). The patient was able to walk without support one year postoperatively, and he was asymptomatic, free of tumor, and unimpaired functionally at the twenty-four-year follow-up (Fig. 1-C).

CASE 2. A thirty-five-year-old woman had pain in the proximal part of the right thigh for three months. Roentgenograms showed an indistinct lytic lesion measuring 3.5 by 2.0 centimeters in the subtrochanteric region of the femur (Fig. 2-A). An open biopsy showed the lesion to be a low-grade chondrosarcoma.

At operation, the proximal quarter of the right femur was excised, and the head and neck of the femur were discarded. A long-stem Austin Moore prosthesis and the diaphysis of the excised segment of the femur were autoclaved as a unit and implanted. Massive fresh autogenous bone grafts were inserted, extending from the calcar to a level five centimeters distal to the site of the osteotomy.

Eleven years after the operation, the patient began to have increasing pain in the groin and the anterior part of the thigh that worsened with weight-bearing and motion of the hip. Roentgenograms revealed some resorption of bone at the calcar femorale and some evidence of loosening of the stem of the prosthesis (Fig. 2-B). Consequently, in 1978, at another institution, a cemented total hip prosthesis was inserted, and a generous amount of bone was removed from the base of the femoral neck. The removed specimen, which was made available to us, contained no tumor. The patient was again seen by us nineteen years after the original operation (Fig. 2-C). At that time she had no evidence of recurrence. She walked with a mild Trendelenburg gait and used a cane some of the time. She had an excellent range of motion, but she complained occasionally of pain after walking long distances. She did not use analgesics.

CASE 3. A forty-three-year-old woman had pain in the left shoulder, and she was found to have a lytic lesion of the head and neck of the humerus. She had had curettage three months previously at another hospital, where a biopsy of the material had revealed a low-grade chondrosarcoma. The proximal twelve centimeters of the right humerus was resected and the patient was treated in the same manner as the patient in Case 2, except that the articular surface was removed and an uncemented proximal humeral prosthesis was inserted. Ten years after the operation, adenocarcinoma of the colon developed. This was treated by resection of the bowel and a primary anastomosis. Seventeen years after the operation on the shoulder, the patient was active, playing golf regularly during the summer. She had some weakness of the muscles of the shoulder girdle but she had a functional range of motion and did not use analgesics. At the time of writing, neither the chondrosarcoma nor the adenocarcinoma had recurred.

CASE 4. A sixty-year-old man had a poorly differentiated chondrosarcoma of the subtrochanteric region of the right femur. He was not considered a suitable candidate for segmental resection because the lesion was anaplastic. However, because he refused to have an amputation, the procedure that was performed in Case 2 was carried out. As noted in our previous report²², widespread metastases developed, and the patient died five years after the operation.

CASE 5. A forty-five-year-old woman had pain in the left shoulder that was not associated with activity. A roentgenographic examination demonstrated a calcific intramedullary lesion of the head and neck of the left humerus, and an open biopsy showed a well differentiated chondrosarcoma. The procedure that was performed in Case 3 was performed for this patient as well. Seventeen years later, the patient was well and was able to do her own housework. The shoulder had a decreased range of motion, with a combined range of scapulothoracic and scapulohumeral abduction of 50 degrees. However, the shoulder could sustain abduction against gravity and slight additional resistance. The patient did not take analgesics.

CASE 6. A forty-three-year-old woman had pain in the left shoulder for seven years, the symptoms having become increasingly severe in the year before the index treatment. She had a large calcific intramedullary lesion of the head and neck of the humerus, and an open biopsy proved the lesion to be a low-grade chondrosarcoma.

The same procedure that was used in Cases 3 and 5 was performed. The patient was last seen in 1974, after which time she was lost to follow-up. However, we learned that she died in another hospital in 1984, and the cause of death was recorded as "acute respiratory and renal failure due to chronic granulocytic leukemia" on the death certificate.

CASE 7. A fifty-four-year-old man had increasing pain in the right shoulder for three years. Roentgenograms showed an intramedullary lytic area with calcific deposits extending into the head and neck of the humerus. An open biopsy demonstrated a low-grade chondrosarcoma. The patient was operated on in the same manner as were the patients in Cases 3, 5, and 6.

Eight years after the operation, a well localized form of Hodgkin disease developed. Fifteen years after the index operation, there was no recurrence of the chondrosarcoma. The Hodgkin disease was under control, and the patient remained employed as an administrator in a school. He reported having no impairment of the shoulder, and he did not take analgesics. The function of the shoulder was very similar to that of the patients in Cases 3, 5, and 6.

CASE 8. A fifty-one-year-old woman underwent a biopsy of a lytic and calcified intramedullary lesion of the head and neck of the right humerus after having had pain for three years. Biopsy confirmed a diagnosis of low-grade chondrosarcoma. The operation was carried out in the same manner as in Cases 3, 5, 6, and 7.

Fourteen years later, the patient had no evidence of recurrence, and she reported that she had no disability even though she had significant weakness of the shoulder. She did not use analgesics.

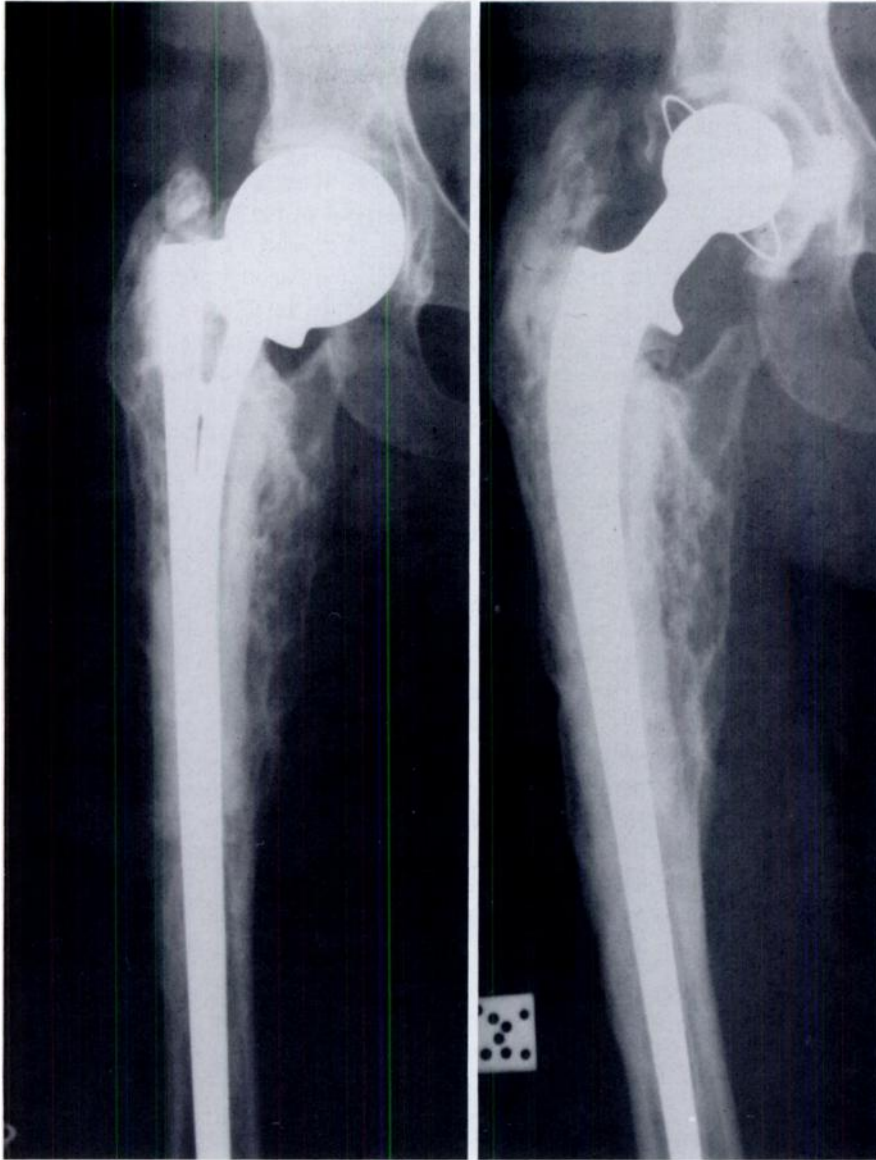


FIG. 2-B

FIG. 2-C

Fig. 2-B: Eleven years postoperatively, the site of the osteotomy is still evident although it has healed. The density of the lateral part of the cortex of the autoclaved segment resembles that of the parent bone, but the medial part of the cortex remains dense, with a heavy concentration of mature callus medially.

Fig. 2-C: Nineteen years after the index procedure and eight years after revision to a total hip arthroplasty, the density of the medial and lateral parts of the cortex of the autoclaved segment more closely resembles that of the distal segment.

Discussion

The use of autoclaved autogenous bone has been reported by several investigators^{1,9-11,24}. The advantages of its use for large defects are ease of procurement, absence of the problems that are associated with storage and dimensional requirements, ensured sterility, and probable avoidance of an immunological response.

In our patients, the sequence of roentgenographic changes followed a consistent pattern. Callus appeared around the autoclaved segment and was well established after two to three months. This response corresponded to the area of the autogenous iliac-bone grafts. Remodeling continued for as long as one year, at which time the external callus had matured. An outline of the autoclaved segment remained for at least fourteen years. In the patient who was

seen at twenty-four years, part of the original implanted segment still was evident. Despite osseous bridging across the site of osteotomy, the line of the osteotomy was still patent after five years in all of the patients. Elongation of the greater and lesser trochanters was found in the only patient (Case 2) in whom the tendons of the gluteus medius and iliopsoas were reinserted to the autoclaved segment (Fig. 2-C).

The roentgenographic appearance of blending of the trabecular pattern of the autoclaved and the viable bone strongly suggests that living bone becomes incorporated into the area of the autoclaved segment. The fact that the site of the osteotomy was completely bridged lends additional support to this hypothesis.

The principal roentgenographic changes took place in

the first four years after operation, but they continued in a more subtle manner over the next two decades. In the patient who had the longest follow-up, there was still some residual remnant of the autoclaved segment after twenty-four years.

It should be noted that although none of the shoulder prostheses were cemented in the medullary canal, no adjacent bone around the prostheses was absorbed. The small amount of osseous absorption of the neck of the humerus may have been the result of remodeling due to stress-shielding.

One patient (Case 2) had a revision to a total hip arthroplasty eleven years after the initial hemiarthroplasty (Figs. 2-A, 2-B, and 2-C). At the time of the revision, a generous specimen of bone was removed from the base of the previously autoclaved femoral neck. The entire specimen was viable except for a few small necrotic spicules that were entombed in the live bone. Since the graft of iliac bone (most of which probably was not viable) extended up to but not proximal to the intertrochanteric line, it is unlikely that the fresh autogenous bone grafts were part of the new bone that was found at biopsy. The scalloped borders of the dead bone corresponded exactly to those of the live bone. No osteoclasts were found adjacent to the spicules. It appears that the only remnants of the segment that had been autoclaved eleven years previously were the small dead spicules, and the biopsy specimen consisted mostly of live bone.

The functional result for the five patients who had a replacement of the shoulder was not excellent, as was the result in the patients who had a femoral lesion, but none of

the patients reported having any major disability. All could initiate abduction and sustain it at 45 degrees against gravity and slight additional resistance; all demonstrated weakness of the shoulder. None of the patients used any analgesics for pain, and none had any impairment of function of the elbow, wrist, or hand. All had mild absorption of bone at the neck of the humerus.

A second malignant lesion (adenocarcinoma of the colon, Hodgkin disease, or chronic granulocytic leukemia) developed in three of the seven patients. The risk of development of a second primary malignant lesion has been studied for several individual neoplasms^{2,12,15,18,19,21}, and it has ranged from very low in patients who have cancer of the cervix² to relatively high in patients who have cancer of the head and neck^{15,21}. To our knowledge, no reports have specifically addressed the risk in patients who have chondrosarcoma.

Obviously, no conclusions can be reached on the basis of this small clinical series. The few laboratory investigations of the use of autoclaved autogenous bone have been both inconclusive and conflicting^{3,4,13,14}. Until the differences between the results of clinical and laboratory studies can be reconciled, we strongly advise caution in considering a wide application of this procedure. The operation is especially attractive because it offers a simplified approach to a complex problem. However, the encouraging clinical results only serve to emphasize the need for careful delineation of the indications for this procedure and for investigation in the laboratory of the problems that are inherent in the implantation of dead tissue.

References

- BOYTCHEV, B.: Operative Treatment of Malignant Para-Articular Bone Tumors. *In* Operative Treatment of Bone Tumors. Third International Symposium, pp. 41-48. Edited by George Chapchal. Stuttgart, Thieme, 1970.
- CLARKE, E. A.; KREIGER, NANCY; and SPENGLER, R. F.: Second Primary Cancer following Treatment for Cervical Cancer. *Canadian Med. Assn. J.*, **131**: 553-556, 1984.
- COUPLAND, B. R.: Experimental Bone Grafting in the Canine: The Use of Autoclaved Autogenous Normal Tibial Bone. *Canadian Veter. J.*, **10**: 170-175, 1969.
- DELEU, J., and TRUETA, J.: Vascularisation of Bone Grafts in the Anterior Chamber of the Eye. *J. Bone and Joint Surg.*, **47-B(2)**: 319-329, 1965.
- ENNEKING, W. F., and SHIRLEY, P. D.: Resection-Arthrodesis for Malignant and Potentially Malignant Lesions about the Knee Using an Intramedullary Rod and Local Bone Grafts. *J. Bone and Joint Surg.*, **59-A**: 223-236, March 1977.
- ENNEKING, W. F.; EADY, J. L.; and BURCHARDT, HANS: Autogenous Cortical Bone Grafts in the Reconstruction of Segmental Skeletal Defects. *J. Bone and Joint Surg.*, **62-A**: 1039-1058, Oct. 1980.
- ENNEKING, W. F.; SPANIER, S. S.; and GOODMAN, M. A.: A System for the Surgical Staging of Musculoskeletal Sarcoma. *Clin. Orthop.*, **153**: 106-120, 1980.
- ERIKSSON, A. I.; SCHILLER, ALAN; and MANKIN, H. J.: The Management of Chondrosarcoma of Bone. *Clin. Orthop.*, **153**: 44-66, 1980.
- EVANS, J. E.; HARVEY, J. P., JR.; and NICKEL, V. L.: Follow-up Notes on Articles Previously Published in The Journal. A Nineteen-Year Follow-up of Chondrosarcoma of the Proximal Portion of the Femur Treated by Resection, Autoclaving, and Bone Replacement. *J. Bone and Joint Surg.*, **51-A**: 598-600, April 1969.
- HARRINGTON, K. D.; JOHNSTON, J. O.; KAUFER, H. N.; LUCK, J. V., JR.; and MOORE, T. M.: Limb Salvage and Prosthetic Joint Reconstruction for Low-Grade and Selected High-Grade Sarcomas of Bone after Wide Resection and Replacement by Autoclaved Autogenic Grafts. *Clin. Orthop.*, **211**: 180-214, 1986.
- JOHNSTON, J. O.; HARRIES, T. J.; ALEXANDER, C. E.; and ALEXANDER, A. H.: Limb Salvage Procedure for Neoplasms about the Knee by Spherocentric Total Knee Arthroplasty and Autogenous Autoclaved Bone Grafting. *Clin. Orthop.*, **181**: 137-145, 1983.
- KANTOR, A. F.; McLAUGHLIN, J. K.; CURTIS, R. E.; FLANNERY, J. T.; and FRAUMENI, J. F., JR.: Risk of Second Malignancy after Cancers of the Renal Parenchyma, Renal Pelvis, and Ureter. *Cancer*, **58**: 1158-1161, 1986.
- KOHLER, P.: Reimplantation of Bone after Autoclaving: Reconstruction of Large Diaphyseal Defects in Rabbits. Stockholm, Karolinska Institute, 1986.
- KU, J. L.; SMITH, P. A.; GOLDSTEIN, S. A.; and MATTHEWS, L. S.: An Experimental Investigation of the Fate of Autogenous Autoclaved Bone Grafts. *Orthop. Trans.*, **9**: 340, 1985.
- LEFOR, A. T.; BREDENBERG, C. E.; KELLMAN, R. M.; and AUST, J. C.: Multiple Malignancies of the Lung and Head and Neck: Second Primary Tumor of Metastasis? *Arch. Surg.*, **121**: 265-270, 1986.
- MANKIN, H. J.; DOPPELT, SAMUEL; and TOMFORD, WILLIAM: Clinical Experience with Allograft Implantation. The First Ten Years. *Clin. Orthop.*, **174**: 69-86, 1983.
- MANKIN, H. J.; FOGELSON, F. S.; THRASHER, A. Z.; and JAFFER, F.: Massive Resection and Allograft Transplantation in the Treatment of Malignant Bone Tumors. *New England J. Med.*, **294**: 1247-1255, 1976.
- MIKÉ, VALERIE; MEADOWS, A. T.; and D'ANGIO, G. J.: Incidence of Second Malignant Neoplasms in Children: Results of an International Study. *Lancet*, **2**: 1326-1331, 1982.
- OLSEN, J. H.: Risk of Second Cancer after Cancer in Childhood. *Cancer*, **57**: 2250-2254, 1986.

20. PARRISH, F. F.: Allograft Replacement of All or Part of the End of a Long Bone following Excision of a Tumor. Report of Twenty-one Cases. *J. Bone and Joint Surg.*, **55-A**: 1-22, Jan. 1973.
21. MIKE, VALERIE; MEADOWS, A. T.; and D'ANGIO, G. J.: Incidence of Second Malignant Neoplasms in Children: Results of an International Study. Cell Carcinoma of the Maxillary Sinus. *Cancer*, **58**: 1122-1125, 1986.
22. SMITH, W. S., and SIMON, M. A.: Segmental Resection for Chondrosarcoma. *J. Bone and Joint Surg.*, **57-A**: 1097-1103, Dec. 1975.
23. SMITH, P. A.; KU, J. L.; GOLDSTEIN, S. A.; and MATTHEWS, L. S.: A Biomechanical Study of Autoclaved Autogenous Bone. *Orthop. Trans.*, **8**: 495, 1984.
24. THOMPSON, V. P., and STEGGALL, C. T.: Chondrosarcoma of the Proximal Portion of the Femur Treated by Resection and Bone Replacement. A Six-Year Result. *J. Bone and Joint Surg.*, **38-A**: 357-367, April 1956.

Copyright 1988 by The Journal of Bone and Joint Surgery, Incorporated

Non-Union of Fractures of the Distal End of the Humerus*†

BY GARY ACKERMAN, M.D.‡, AND JESSE B. JUPITER, M.D.‡, BOSTON, MASSACHUSETTS

From the Department of Orthopaedic Surgery, Massachusetts General Hospital and Harvard Medical School, Boston

ABSTRACT: The records of twenty patients who had been treated for a non-union of the distal end of the humerus at the Massachusetts General Hospital from 1968 to 1984 were reviewed. Thirteen of the fractures were extra-articular and seven were intra-articular. Seven fractures had been open and nine had been associated with multiple trauma. Eight had been initially treated by open reduction and internal fixation; five, by closed reduction and immobilization; four, by skeletal traction; two, by external fixation; and one, by débridement and immobilization.

The average time from the original fracture to the treatment of the non-union was twenty months (range, three to 120 months). All but one patient had pain and instability, and fifteen (75 per cent) had limited motion of the elbow. Radiographically, eleven were considered to have a reactive non-union and nine, a non-reactive non-union. Seventeen (94 per cent) of the eighteen non-unions ultimately united. Two patients underwent excision of the distal end of the humerus and replacement with an allograft.

At follow-up (average, 3.6 years), function in one patient was rated as excellent; in six, as good; in seven, as fair; and in six, as poor. The patients who had an extra-articular supracondylar non-union had the best over-all results, while those who had a non-union that was associated with an intra-articular component or severe soft-tissue trauma did less well.

It should be emphasized, however, that most of the patients in this study continued to have a major long-term disability, despite the fact that union was successful.

Fractures of the distal end of the humerus are often difficult to treat, and non-unions at this location are uniquely troublesome. The functional disability is often profound because of limitation of motion, instability, and pain. The meager skeletal support of the articular surfaces of the distal end of the humerus makes successful internal fixation a technical challenge^{2,6,7,11,14,16,23,26,30,32}.

Despite an increasing interest in the operative treatment of fractures and their sequelae, there is a paucity of literature regarding the management of non-unions of the distal end of the humerus^{9,10,17,18,21,24,27,28}. This can be attributed partly to the fact that these fractures are uncommon. It has been estimated that only 2 per cent of all fractures involve the distal end of the humerus and that only 2 per cent of these fractures will result in non-union^{27,33}.

This paper is a review of a series of twenty non-unions of the distal end of the humerus that were treated over a sixteen-year period. The purpose was to identify the reasons for the non-unions, highlight the surgical methods used to gain union, and assess the functional outcomes of treatment.

Materials and Methods

Between 1968 and 1984, twenty-three patients were treated for a non-union of the distal end of the humerus at the Massachusetts General Hospital. Twenty of the patients were available for follow-up and formed the basis of this study. Fifteen patients were men and five were women. The average age was forty years (range, twenty to seventy years).

Thirteen non-unions involved the left humerus and seven, the right. All twenty non-unions occurred after a traumatic, non-pathological fracture (Table I). Seven of the original fractures were the result of a low-energy injury, such as a fall in the home, and thirteen were secondary to high-energy trauma, such as a fall from a height or a motorcycle accident. Seven fractures were open: two were Grade I, four were Grade II, and one was Grade III¹³. Associated injuries included multiple trauma (three patients), ipsilateral radial or ulnar fracture (three patients), combined

* No benefits in any form have been received or will be received from a commercial party related directly or indirectly to the subject of this article. No funds were received in support of this study.

† Read at the Annual Meeting of American Shoulder and Elbow Surgeons, San Francisco, California, January 21, 1987.

‡ Department of Orthopaedic Surgery, Ambulatory Care Center 427, Massachusetts General Hospital, Boston, Massachusetts 02114.